



Right')

Story and photos by **Dr. Eric C. Lindquist, DMV**
For Veterinary Practice News

A mobile sonographer and veterinary medical consultant faces daily challenges. We must strive to resolve the cases that general practitioners are scratching their heads about.

The clinical exam, diagnostic workup, consultations among able colleagues and elimination of the straightforward has usually already been performed before we walk through the door.

The case is placed in front of us and our client says, "Tell us what is going on, Doc." Naturally, using ultrasound and interpreting the images and video clips produced cannot resolve every case of internal medicine.

But we strive to at least give our client a direction toward resolution.

The following case studies are three novel examples of cases that had our clients scratching their heads, wondering what was going on. Their patients' owners were on the verge of deciding upon euthanasia because of frustration and expense.

We have all been in this position as clinicians and can certainly identify with the scene.

The format presented here demonstrates the highlights of the clinical workup that had been performed before the sonogram, the description of the sonogram and the outcome.

The workups are not necessarily ideal or perfect, but represent a real-world presentation in which the referring clinician sought a rapid and efficient diagnosis based on economic abilities of the owner. This is the historical account of how these cases developed and concluded.

CASE 1: BRUNO

History: A 3-year-old male neutered pug presented for a sudden onset of vomiting, anorexia and diarrhea, after a few weeks of "not doing right" as reported by the owner. Severe abdominal pain was noted on physical exam. The CBC revealed moderate leukocytosis with a left shift, normal blood chemistry other than mild serum alkaline phosphatase elevation, and mild hypokalemia. The patient was only partially responsive to fluid therapy over a 48-hour period.

Clinical Differential Diagnosis: Foreign body, gastroenteritis,

pancreatitis, intussusception, intestinal torsion, GDV, neoplasia. **Sonographic Interpretation:** The proximal duodenal lumen is focally distended, with an echogenic structure. Lack of accompanying distal acoustic shadowing could support soft, porous intraluminal material. In the far field, mild localized omental inflammation is present, suggesting an emerging localized peritonitis.

Sonographic Diagnosis: Duodenal foreign body.

Sampling: Exploratory enterotomy revealed a baby bottle nipple lodged in the mid duodenum. Mild localized peritonitis was present at the site of obstruction. The baby bottle nipple was surgically removed from the mid-descending duodenum.

Outcome: The patient responded well to surgery and hospitalization. The owner reported that she had been missing the baby bottle nipple for over a month. It was assumed that the foreign body most likely remained in the stomach for some time, causing mild and vague symptoms until passage into the duodenum stimulated a more aggressive clinical profile.

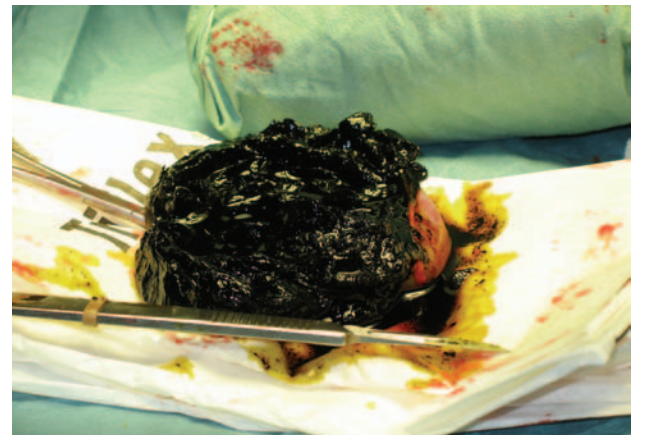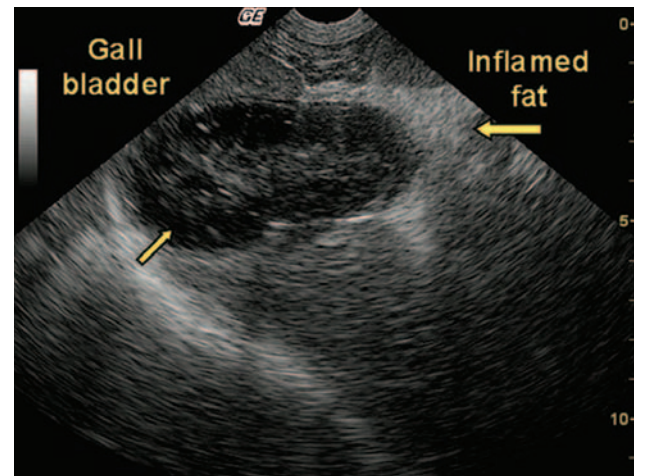
CASE 2: CODY

History: A 12-year-old MN canine mix presented for two weeks of diarrhea and partial anorexia. Icterus was evident on an otherwise normal physical exam. The preliminary blood chemistry profile demonstrated severe SAP and moderate alanine transferase and cholesterol elevations, with severe hyperbilirubinemia. The urinalysis revealed 3+ hyperbilirubinuria with normal concentration.

Clinical Differential Diagnosis: Hepatic or other neoplasia, biliary obstruction/mucocoele, inflammatory hepatopathy, pancreatitis with post hepatic obstruction, IBD, infectious disease.

Sonographic Interpretation: Image 1: This image shows a moderate to markedly thickened hypoechoic gallbladder wall. The gallbladder is severely distended, with echogenic stationary sediment. The intraluminal sediment (small arrow) extends distally into the proximal cystic duct region resulting in dilation. Pericystic increased fat echogenicity is also present, suggestive of perforation or inflammation (large arrow).

Sonographic Differential Diagnosis: Cholecystitis and gall-



EDUCATION SERIES

ADR, from Page 12

bladder mucocele with possible perforation.

Sampling: A 16-gauge ultrasound-guided liver biopsy revealed mild to moderate, chronic, active, fibrosing cholangiohepatitis, largely excluding concurrent hepatic neoplasia such as lymphoma. Therefore, cholecystectomy for the mucocele, gastrotomy for a concurrent leather foreign body and intestinal resection for coexisting leiomyosarcoma were then performed at a surgical referral facility. Gallbladder mucocele, infarction and cholangiohepatitis were confirmed in the postoperative histopathological examination.

Image 2 shows an intraoperative view of the distended gallbladder.

Image 3 is of the open gallbladder mucocele after surgical removal.

Comments: Persistent, moderately elevated SAP values were present but stable over the next three months, with resolution of clinical symptoms after a problematic week of postoperative therapy. The patient thrived in this postoperative period until it presented for unexplained abdominal pain and anorexia three months post-discharge. The follow-up sonogram revealed a stricture at the distal right ureter (Image 4), and resultant chronic hydronephrosis of the right kidney with 60 percent reduction in renal size from the sonogram three months earlier (Image 5). Right nephrectomy/ureterectomy was performed at the general practi-

tioner's facility, given that the owner could no longer afford surgical referral. Adhesion from the previous surgery for intestinal leiomyosarcoma was the cause of the ureter stricture. Cody was thriving and asymptomatic at a 6-month follow-up.

CASE 3: TOM

History: A 7-year-old MN domestic short-hair presented for dysuria and a history of persistent UTI. This presentation progressed into episodes of vomiting, weight loss and "not doing right" as reported by the owner over a one-month period. The physical exam revealed a palpable mass in the cranial abdomen that was confirmed by radiographs and positioned caudal to the stomach. The CBC was normal.

Blood chemistry was normal except for minor globulin elevation. Urinalysis (free catch): PH 6.0, USG 1.032, appeared cloudy, leukocytes moderate, protein 100+, epithelia, and bacteria (cocci).

Clinical Differential Diagnosis: UTI/pyelonephritis, urolithiasis, pancreatitis, neoplasia, IBD, infectious disease.

Sonographic Interpretation: A well-circumscribed, hypoechoic mass was positioned within the region of the body of the pancreas. The mesentery and omentum bordering the pancreas was mildly echogenic and may be adhered.

Sonographic Differential Diagnosis: Suspect chronic pancreatitis with mild peri-pancreatic fibrosis, inflammation and adhesions with an accompanying

avascular mass. Differentials for the mass include abscessing or necrotizing neoplasm or focal pancreatitis, sequestration.

Sampling: 22-gauge ultrasound-guided fine needle aspirate was performed on variable hypoechoic portions of the pancreas. Cytology: Marked pancreatitis/steatitis/necrosis. No evidence of neoplasia was found.

Comments: The patient responded well to intravenous fluid support, plasma-expander therapy and endovenous antibiotics. Outpatient therapy included multimodal antibiotics and nutritional support. A single dose of dexamethazone was also administered to reduce inflammation. The patient was essentially asymptomatic for five weeks and antibiotic therapy was stopped. One week later the patient again presented for lethargy and anorexia. A follow-up sonogram was performed with power-flow Doppler six weeks post-therapy. The residual mass was continuous with the right limb which was mildly enlarged, hypoechoic, with evidence of normal perfusion noted with power flow Doppler. A concurrent splenic abscess was found on sonogram that most likely contributed to the symptoms. Tom was again hospitalized and discharged three days later, responding to multimodal antibiotic therapy.

Outcome: Tom is thriving four months after the original presentation. Unfortunately, not all cases turn out this nicely in the clinical world of veterinary ultrasound.

But these presentations represent what we all strive for; a positive outcome for our patients and their owners.

In the midst of a cloud of doubt and frustration, it was the positive spirit and objectivity maintained by the referring clinicians and their patients' owners that allowed the art of veterinary medicine to prevail until a definitive diagnosis was achieved.

This, along with a bit of good fortune, led to a definitively positive result in each case.

Dr. Lindquist, Dipl. ABVP, canine and feline medicine, is manager of the Team New Jersey Mobile Division of Sound Technologies/Veterinary Imaging Associates in Sparta, N.J.

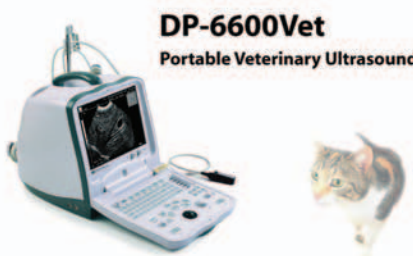
Special Thanks

Dr. Lindquist offers special thanks to these colleagues for their contributions to the case study interpretations presented here:

■ Lee Yanik, DVM, Dipl. ACVR, director of Diagnostic Imaging at Animal Critical Care and Emergency Services in Seattle;


■ Johanna Frank, DVM, DVSc., Dipl. ACVIM (Internal Medicine), of Furlong, Pa.

MINDRAY




DP-6600Vet
Portable Veterinary Ultrasound

- Fully digital processing
- Superior image quality
- Designed for veterinary use
- Multi-frequency transducer up to 10MHz
- 2 USB ports for image storage and report printing



PM-9000Vet
Portable Veterinary Monitor


- 10.4" color TFT with 7 traces
- Up to 72-hour graphic and tabular trends
- Recorder and rechargeable battery
- Mainstream / sidestream EtCO₂
- Parameters: ECG, RESP, SpO₂, NIBP, TEMP, EtCO₂, and Multi-Gas/O₂




BC-2800Vet
Veterinary Hematology Analyzer

- Species: Dog, Cat, Cow, Goat, Pig, Horse, and Buffalo
- 3-part differentiation of WBC for Cat and Dog, 18 parameters+ 3 histograms
- Fully automated, compact, flexible and low-cost
- Up to 10,000 sample results (including histograms) can be stored
- 8-inch color LCD screen
- Very small sampling volume at 13 ul

Distributors Welcome






North America:
Vancouver Office
4885 Kingsway, Suite 311, Burnaby, B.C., V5H 4T2, Canada
Tel: 604-451-1199 Fax: 604-451-1189
Toll free: 800-656-9088 E-mail: usa@mindray.com

MINDRAY USA CORP
171 Locke Dr., Suite 109, Marlborough, MA 01752
Tel: 508-229-0686 Fax: 508-229-0349
Toll free: 888-816-8188 E-mail: usa@mindray.com

Circle No. 159 on Reader Service Card

The best portable ultrasound, but don't take our word for it...




SonoScape

- Tissue Harmonic Imaging
- Compound Imaging
- Continuous Wave Doppler
- Pulsed Wave Doppler
- Color Doppler
- Color Power Doppler
- 15 inch LCD Monitor
- Image and Video Loop Storage
- 20 Transducers Available
- User Presets
- USB Interface For Memory Devices

Dr. Todd Hurst, Owner of Harpeth Valley Animal Hospital:

"The SSI-1000 has exceptional image quality, especially for a mobile unit. We have been totally satisfied with all aspects of the image quality including the Doppler functions in both cardiac and abdominal scans."



ultrasource

www.ultrasource.net

Call 888-680-6989 for a demonstration.

Circle No. 182 on Reader Service Card